

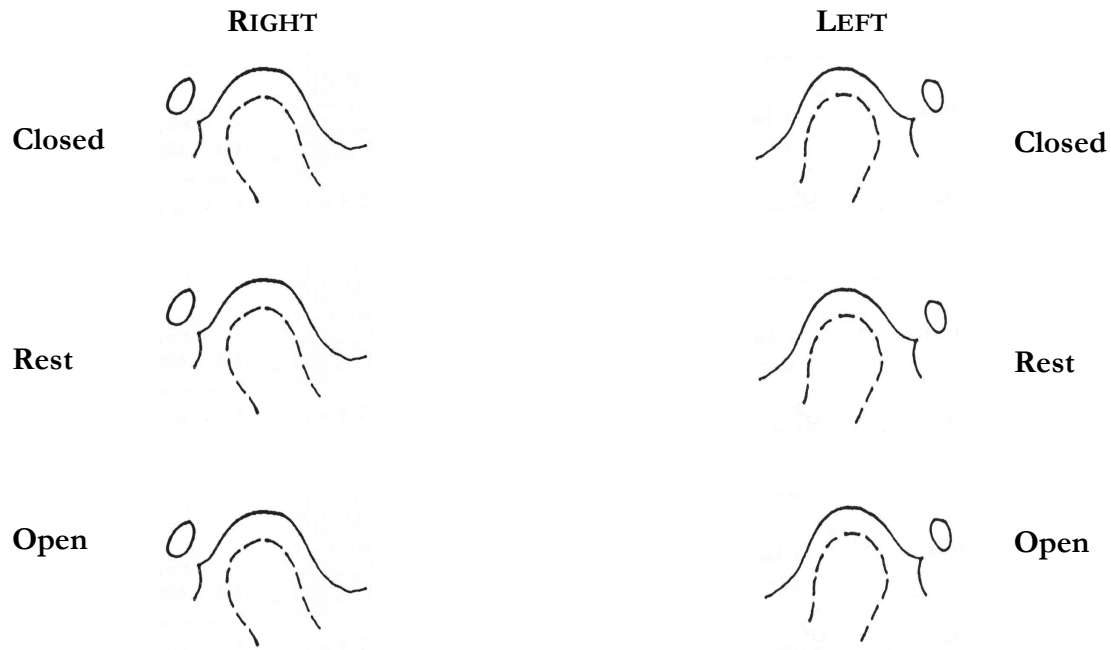


# EVALUATION OF RADIOGRAPHS

## SUBMENTAL VERTEX :

Right Condyle Angle: \_\_\_\_\_ Left Condyle Angle: \_\_\_\_\_

## CORRECTED TRANSCRANIAL:



## PANORAMIC:

Missing Teeth \_\_\_\_\_ Supernumerary Teeth \_\_\_\_\_

Coronoid Hyperplasia Right \_\_\_\_\_ Left \_\_\_\_\_

Eagle's Syndrome Right \_\_\_\_\_ Left \_\_\_\_\_

Ramal Height Right \_\_\_\_\_ Left \_\_\_\_\_

Morphology of Condyle Right \_\_\_\_\_ Left \_\_\_\_\_

Antrums Right \_\_\_\_\_ Left \_\_\_\_\_

Neoplasms \_\_\_\_\_

TOWNS VIEW OF CONDYLES \_\_\_\_\_

TRANS-ORBITAL Right \_\_\_\_\_ Left \_\_\_\_\_

OTHER: \_\_\_\_\_